Augmentation Mammaplasty: Expander Use

HILTON BECKER

Breast augmentation is one of the more gratifying procedures performed by a plastic surgeon. Traditionally, fixed-volume silicone-gel implants or saline-filled implants that are adjusted at the time of surgery have been used. However, patient dissatisfaction with size is the most common problem following breast augmentation. Knowing that the size can only be adjusted with further surgery, the patient usually accepts the original size.

The use of an adjustable implant enables the surgeon to overcome this problem. Furthermore, it also allows for a greater degree of control of the postoperative result, together with the ability to treat a wider range of breast deformities.

Although patients are offered a choice of implants, most select the adjustable implant when the advantage is explained. The implant commonly used is the double-lumen adjustable implant containing a small amount of gel in the outer lumen and having a detachable filling tube entering the inner lumen by means of a self-sealing valve (Fig. 11-21A,B,C). Recently, a textured-surface single-lumen adjustable implant has been used.

In order to determine the size that will be used, sizer implants are placed in the patient's bra. The patient then selects the size that she would like to be, understanding that the size can be adjusted postoperatively by either increasing or decreasing the volume. The sizes most commonly selected are:

200 cc: 60 percent
150 cc: 10 percent
250 cc: 20 percent
Over 250 cc: 10 percent

Postoperatively, most patients elect to have the size increased, especially when the swelling has decreased, the implant has settled in position, and the patient has become used to her new size. The postoperative size increase is usually 20 to 40 percent above that originally selected by the patient.

Incisions

The inframammary incision is used in 50 percent of patients, the transareolar in 30 percent, and the transaxillary in 20 percent.

INFRAMAMMARY INCISION

The inframammary incision is most commonly used in patients who have (1) a distinctive inframammary crease that is easily concealed in a standing position, (2) breast ptosis, and (3) a tight or asymmetrical inframammary crease. The inframammary approach is the easiest incision to use and allows for precise pocket dissection.

PERIAREOLAR INCISION

The periareolar incision is best suited for patients with smaller breasts. The scars are less noticeable than the inframammary incision and can be tattooed if necessary to create an inconspicuous scar. This incision is used for treatment of breast deformities, such as tubular breast, where correction of the deformity can be performed through the same incision.

TRANSAXILLARY INCISION

The transaxillary incision results in the least visible scar with no scarring on the breast. The scar is placed in the crease line in the hair-bearing portion of the axilla. It is used in the younger patient who has some cleavage with no ptosis or tubular deformity. This is, however, the most difficult of the three

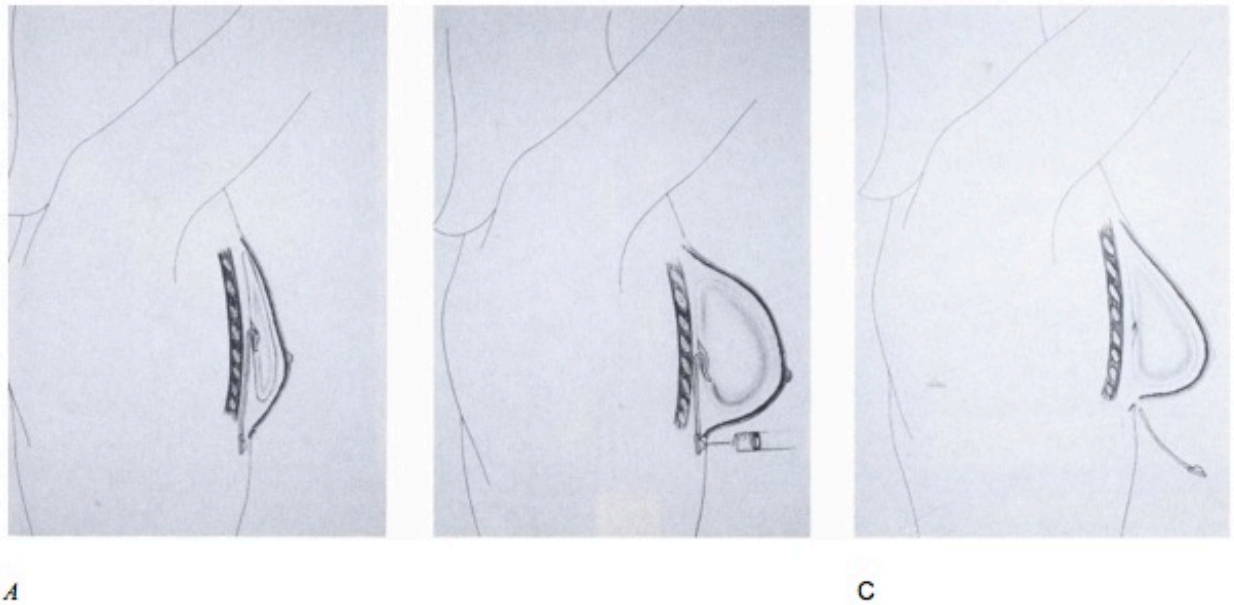

FIG. 11-21. Drawings showing expander mammary prosthesis. A. Implant prior to insertion. B. Implant being filled with saline by means of injection dome. C. Injection dome removed. Note double shell with dual valves.

approaches to perform. It is more difficult to obtain symmetry and good cleavage. Revision of a breast implant after transaxillary augmentation will require a separate inframammary or transareolar incision.

Implant Position

Most implants are placed in a submuscular position, since the incidence of capsular contracture is less and there is a benefit in terms of mammography. In the ptotic breast, the submuscular position offers a greater degree of support to the implant. A subglandular position is used in the following situations:

1. In certain cases of Poland's syndrome
2. In weight lifters
3. In patients who feel that the excess movement would be undesirable
4. In patients who request conversion from submuscular to subglandular position

Patient Evaluation Preoperatively

or tuberosity of the breasts. The incision to be used is determined on the basis of this information.

Surgical Technique

Patients are placed on prophylactic antibiotics prior to surgery. Usually 1 gm cefazolin (Ancef) is given intravenously on call. The inframammary crease and the extent of dissection are marked out on the patient in the standing or sitting position. Local anesthesia with sedation or general anesthetic is used.

INFRAMAMMARY APPROACH

A 3- to 4-cm incision is made in the central portion of the inframammary crease (Fig. 11-22A,B,C) Dissection is then carried down to the underlying pectoralis major muscle. The muscle is identified and incised parallel to the muscle fibers down to the underlying rib. A large submuscular pocket is dissected using blunt finger dissection. Care is taken to free the fibrous band connecting the pectoralis major to the rectus abdominis fascia. Usually blunt dissection suffices, but occasionally it is necessary to perform further dissection using a fiberoptic retractor and the cutting cautery (Fig. 11-22C).

The pocket is irrigated with bacitracin solution (50,000 units in 500 cc saline) prior to insertion of the implant. The implants are rinsed in bacitracin solutions and then placed in the pocket. The rationale for the use of bacitracin is to reduce bacterial contamination intraoperatively. Steroids are not

An evaluation is made as to the general size and shape of the breasts, symmetry, the nature of the inframammary crease, and whether there is ptosis

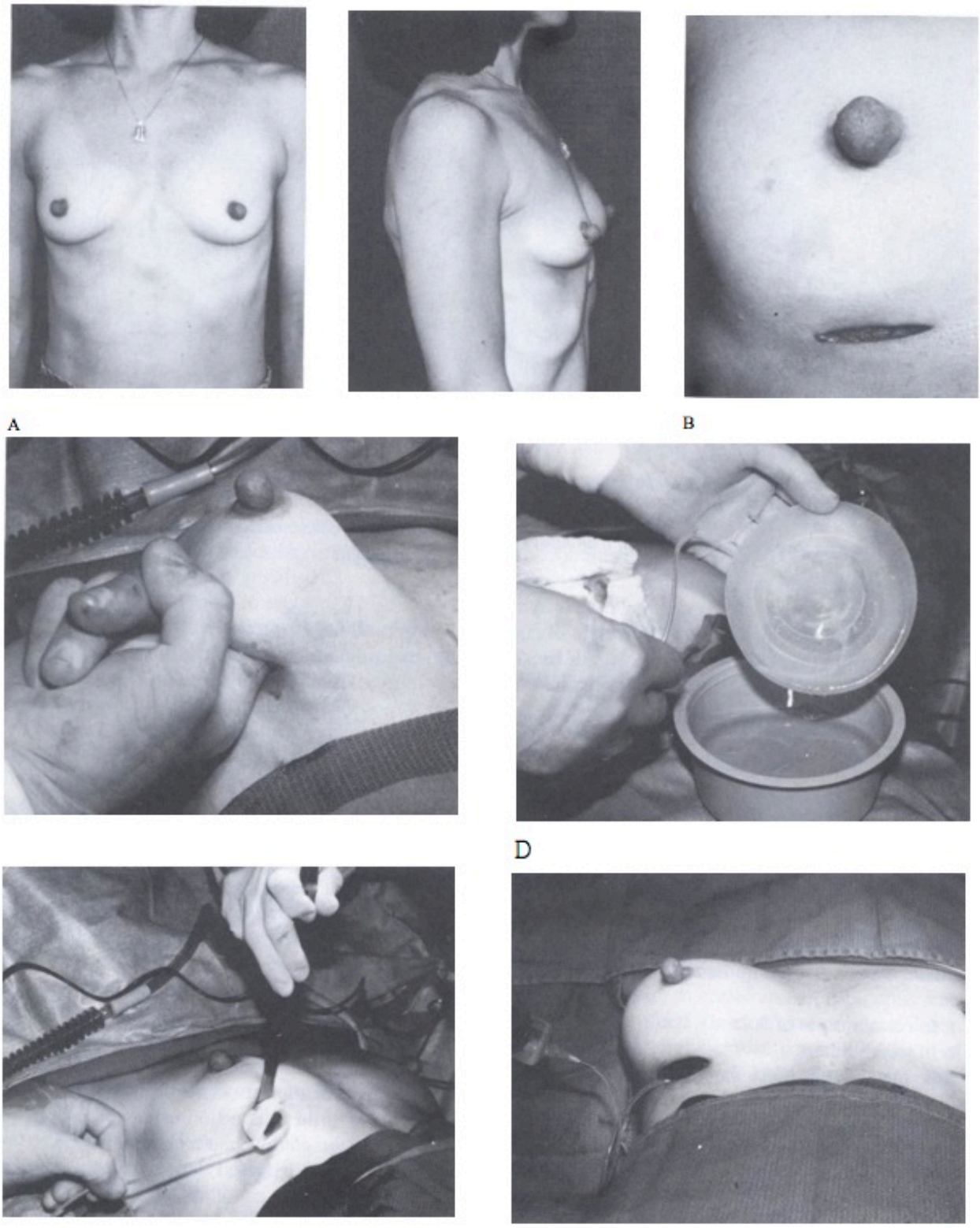

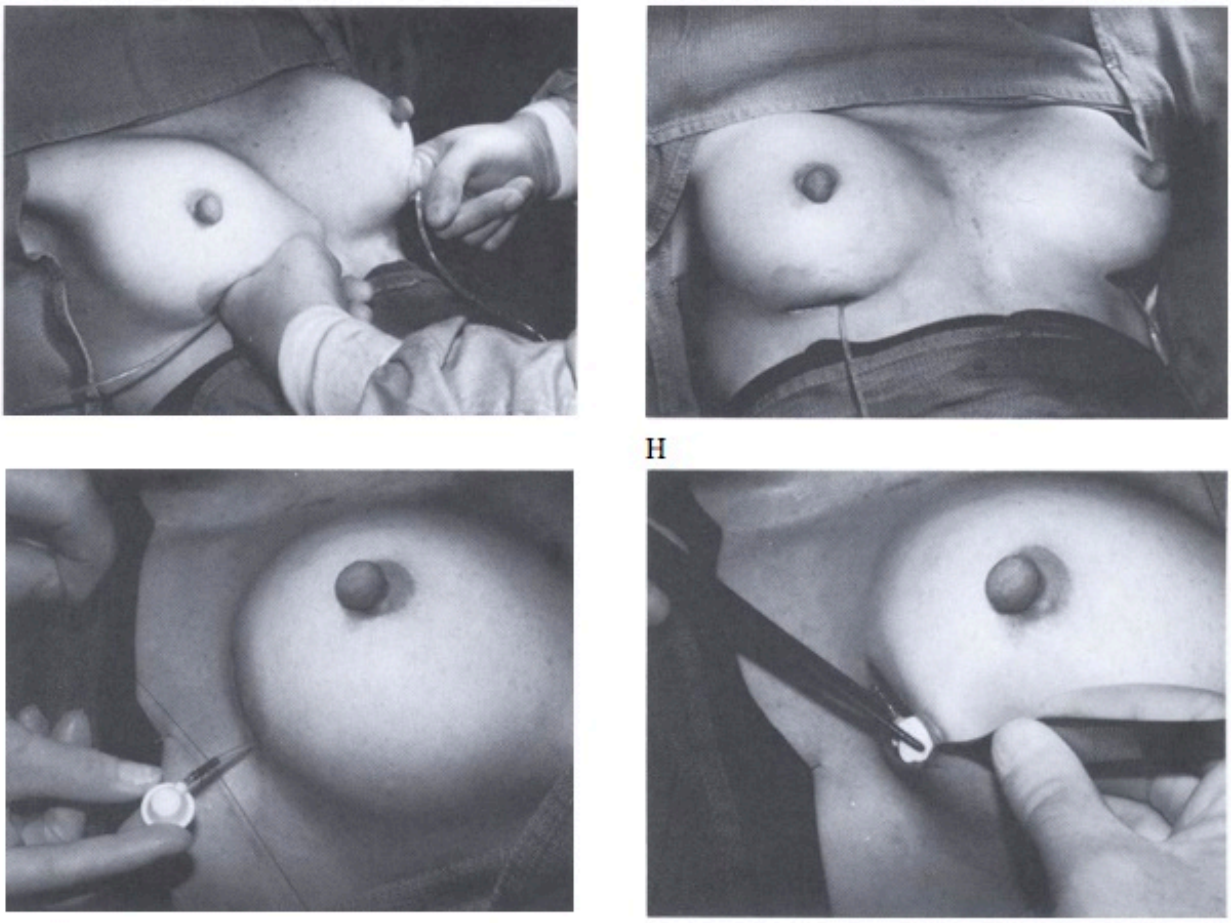

FIG. 11-22. A. Preoperative views, PA and lateral. B. An inframmary incision is made. C. Blunt submuscular dissection is performed. D. Implant is irrigated in bacitracin solution. (In this patient, a single-lumen textured expander implant was used.) E. Implant is inserted into pocket. E Pocket is overexpanded intraoperatively. G. Pocket is further adjusted. H. Symmetry is checked with patient in semisitting position. I. Injection dome is attached to filling tube with 3-0 silk ties. J. Injection dome is placed in subcutaneous pocket close to incision.

used to irrigate the pocket and are not placed within the implant because steroids are known to cause tissue atrophy and pseudoptosis (Fig. 11-22D).

The implants are then filled with saline solution by inserting a blunt 16-gauge needle into the fill tube. The implants are often overexpanded intraoperatively, and further adjustments to the pocket are made with the patient in the sitting position (Fig. 11-22E,F,G,H).

The volume of the implant is then reduced, and the muscle layer is closed with interrupted catgut sutures. A subcutaneous pocket is dissected just lateral to the incision, and the fill tube is cut to the appropriate length. The injection dome is then attached to the fill tube and secured with two silk ties, and the dome is then placed in the subcutaneous pocket secured with a catgut suture. The skin incision is closed in layers using 4-0 interrupted catgut sutures to the subcutaneous tissue and a 5-0 running nylon or Prolene suture to the skin. No drainage is usually necessary (Fig. 11-221,J.

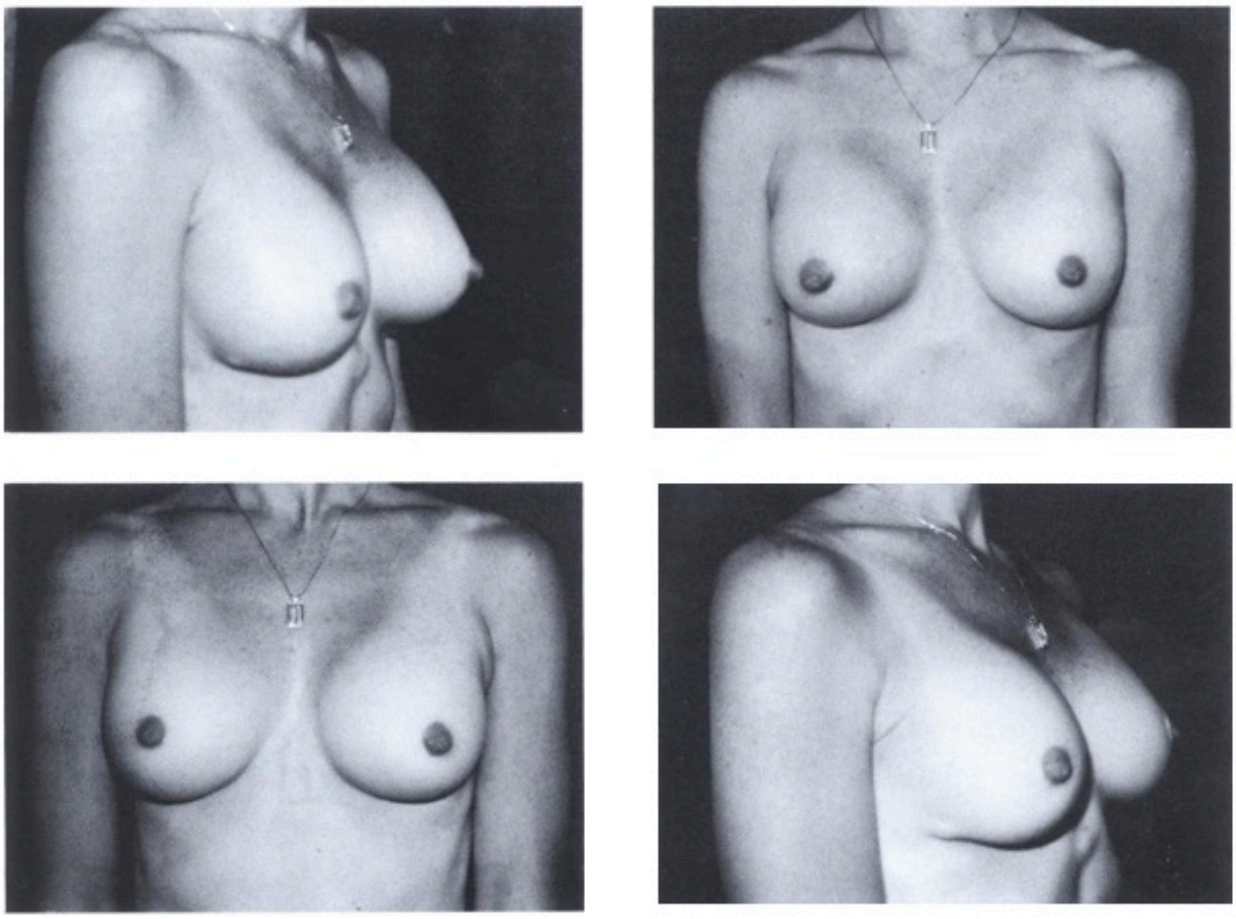

L

FIG. 11-22. (continued) K Early postoperative result. (Nipple reduction has been performed as well.) L. Final result following volume reduction.

Postoperatively, the patient is placed in a bra that is reinforced with an Ace bandage above (Fig. 11-22K,L).

TRANSAREOLAR APPROACH

The incision is confined to the inferomedial aspect of the areolar margin. Dissection is carried out in the subcutaneous plane to the inferior margin of the glandular tissue. The glandular tissue is not incised. The submuscular pocket is then dissected in a similar fashion to the inframammary approach. The injection dome is placed close to the lateral aspect of the incision or beneath the areolar skin (Fig. 11-23A,B,C,D).

TRANSAXILLARY APPROACH

The incision is made in the hair-bearing skin of the axilla in the most prominent crease (Fig. 11-24A,B). Dissection is performed in the subcutaneous plane inferiorly to the lateral edge of the pectoralis major muscle. The submuscular plane is then entered by dissecting between the pectoralis major and minor muscle. The pocket is then dissected using blunt finger dissection assisted by a blunt dissector. Symmetry is always checked with the patient in the sitting position. Intraoperative overexpansion is always helpful in identifying irregularities in the pocket and areas that require further dissection. Correction can then be obtained by placing a blunt dissector beneath the implant and freeing the tethering bands (Figs. *11-24D,E,F,G, 11.25,* and 11-26).

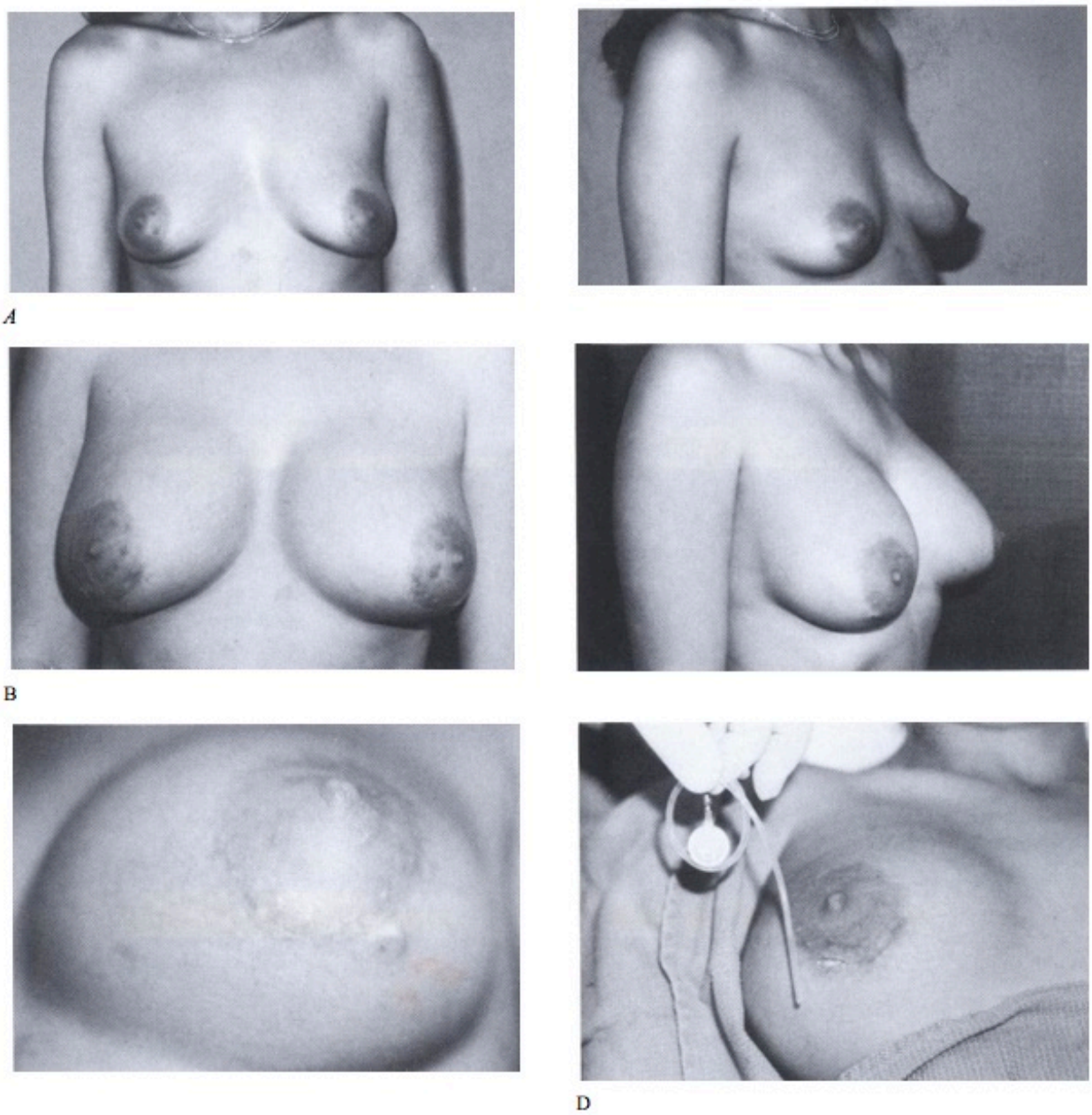

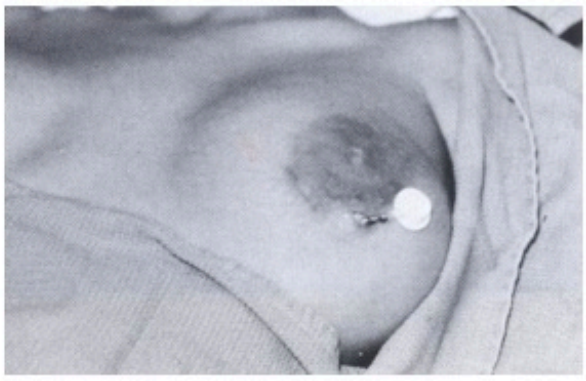

FIG. 11.23. A. Preoperative views of patient with mild ptosis. B. Final result showing correction of ptosis. C. Close.up view of circumareolar scar and injection dome. D. Injection dome removal through original incision.

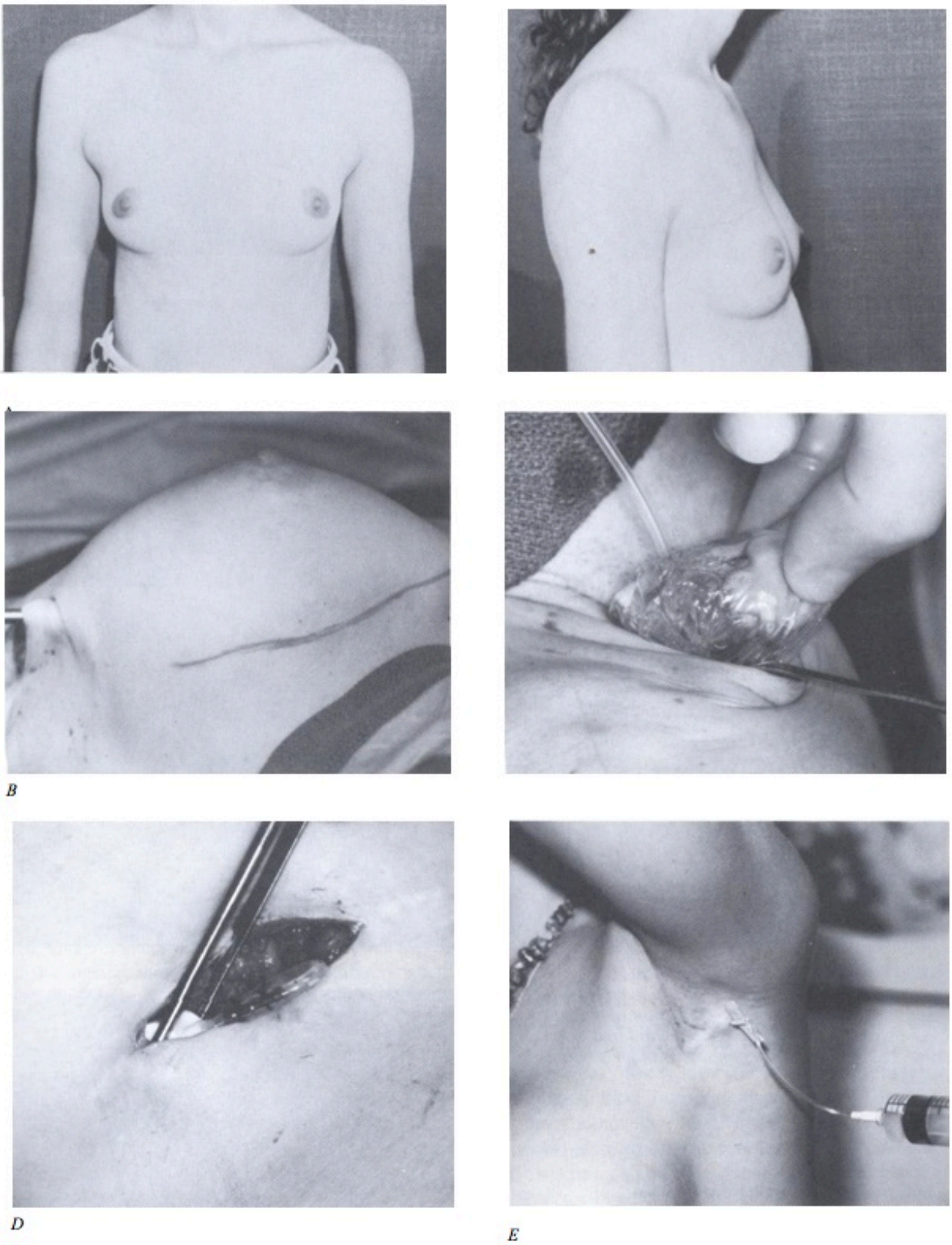

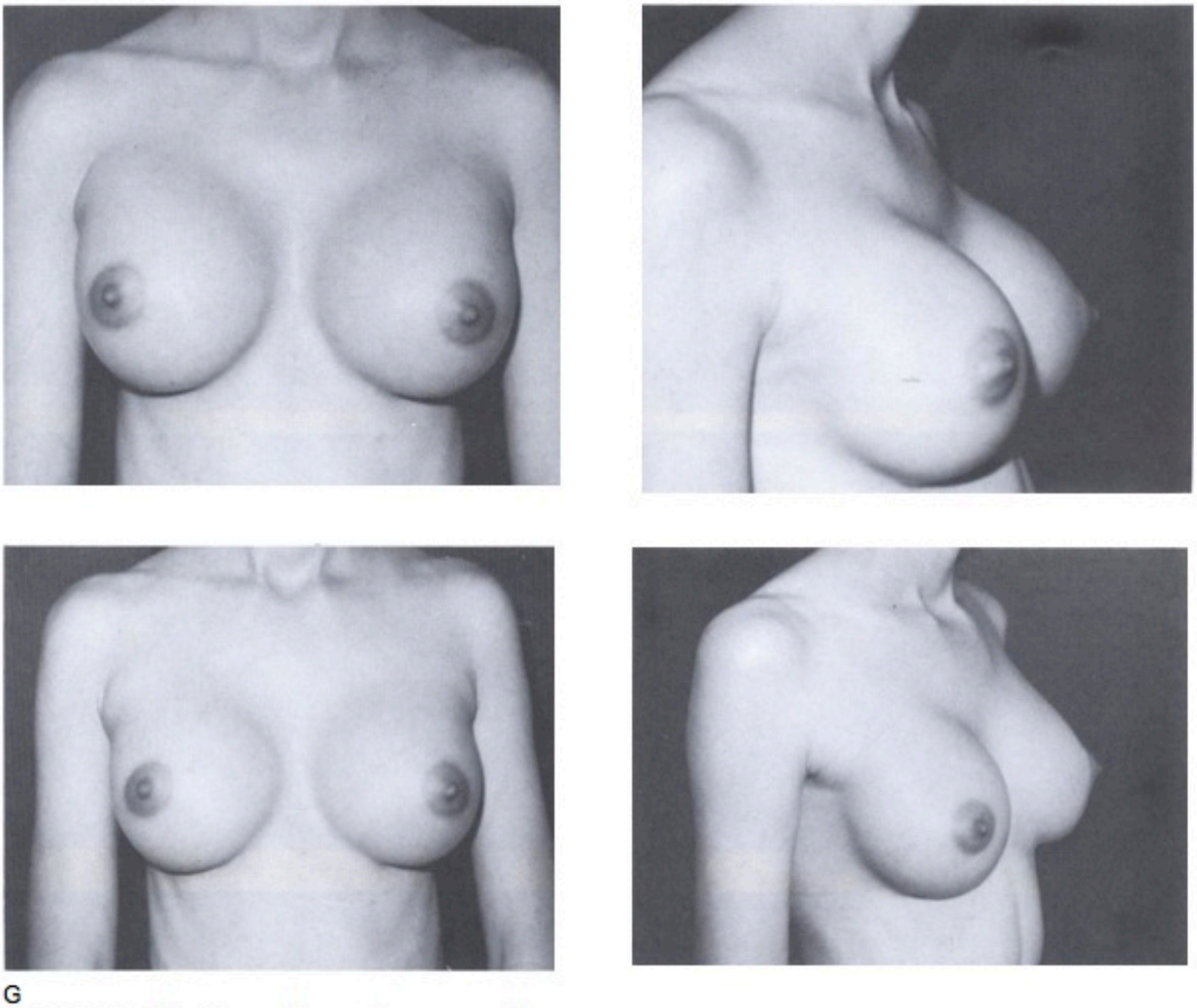

FIG. 11-24. *A. PA and lateral views prior to transaxillary augmentation. B. Submuscular pocket dissected 2 to* 3 *cm below the inframmary crease marking. C. Implant inserted into pocket. D. Placement of injection dome close to incision edge. E. Implant expanded postoperatively using a 23--gauge butterfly needle. F PA and lateral views showing overexpansion. G. Final result following volume adjustment.*

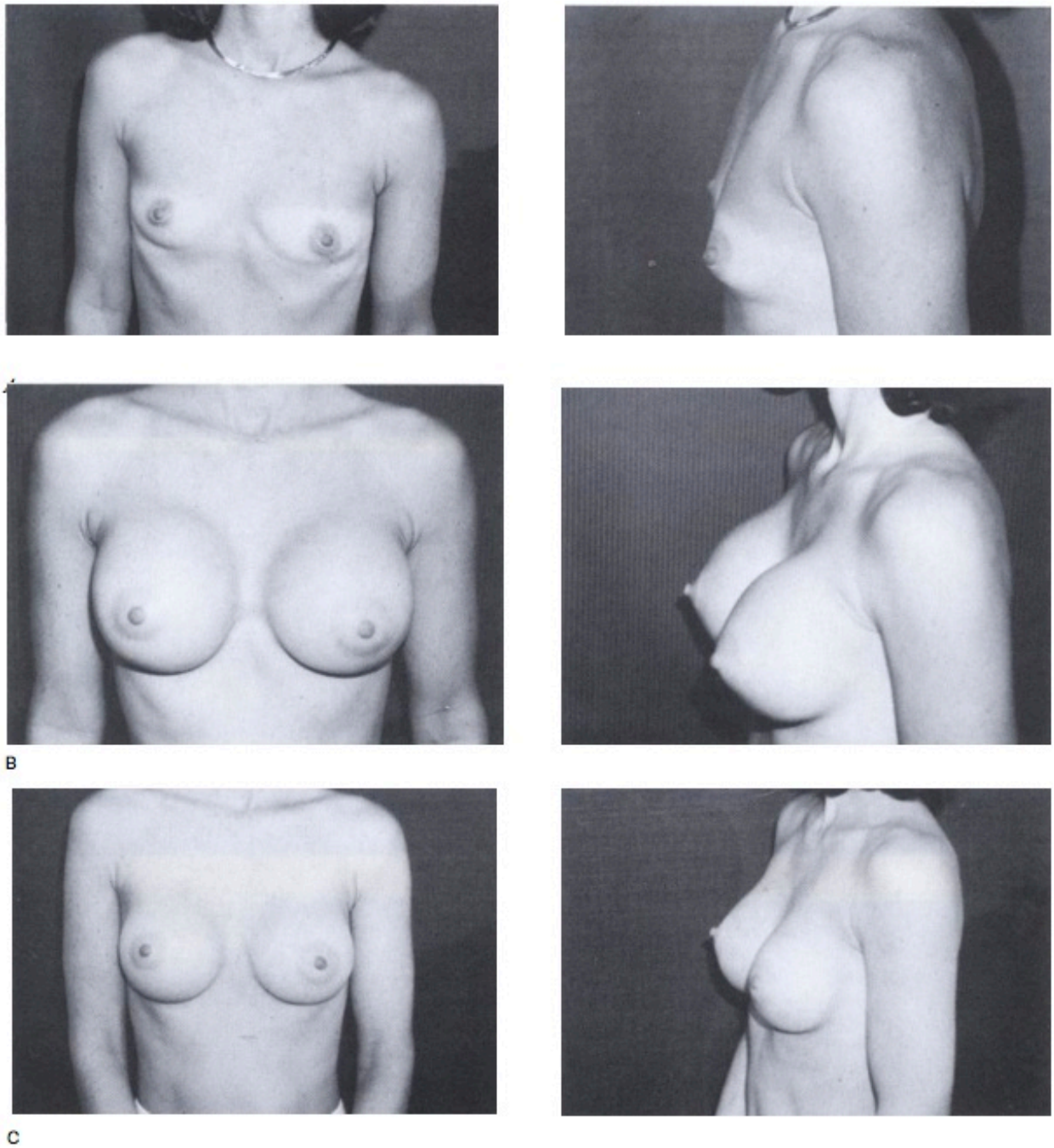

FIG. 11-25. A. Preoperative views. B. Postoperative views following transaxillary submusclar augmentation with implants overexpanded. C. Final result following volume adjustment.

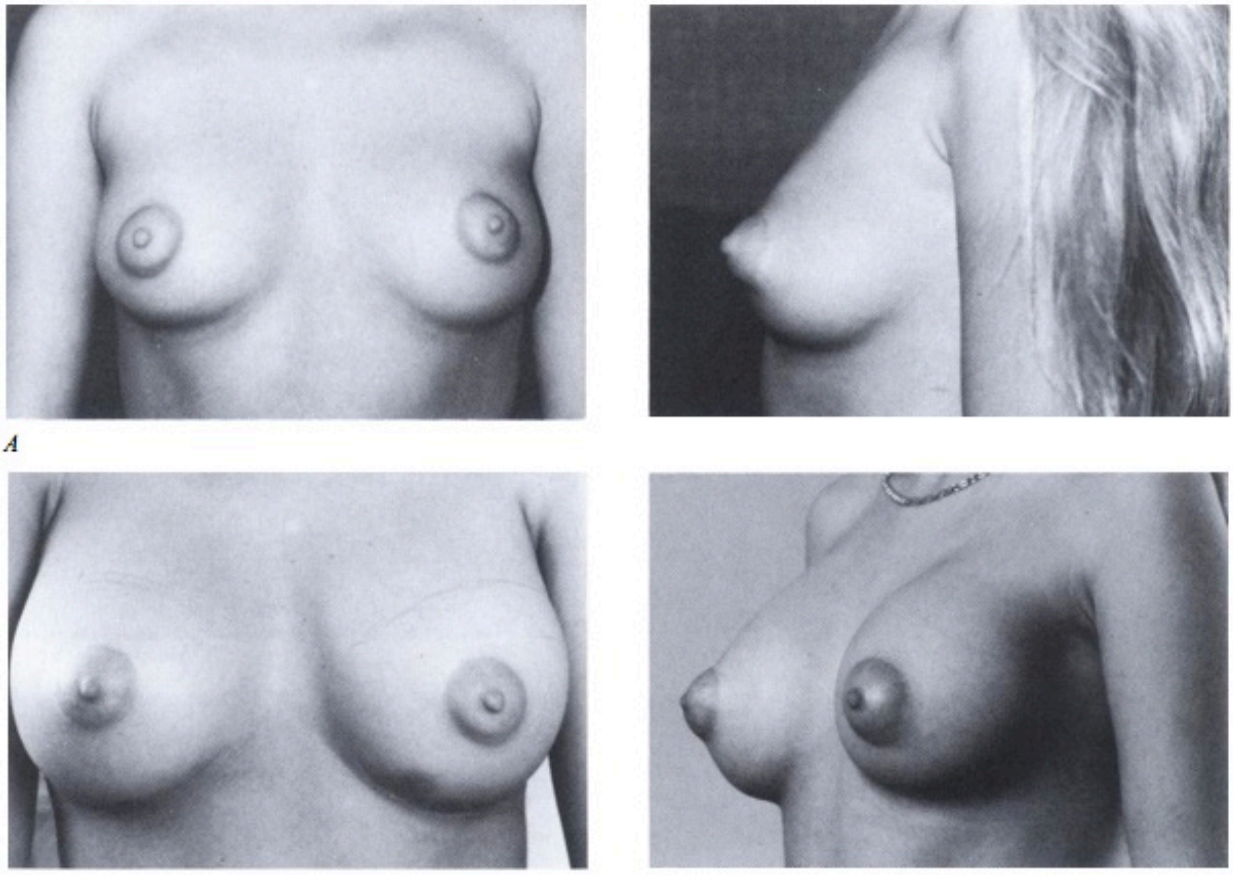

FIG. 11-26. A. PA and lateral views preoperatively. B. PA and lateral views postoperatively. Transaxillary augmentation.

Postoperative Management

The dressings are changed at 24 to 48 hours. If the implants appear to be low, the patient is placed in a bra. If the implants appear to be sitting in a higher position than normal, an elastic strap is placed around the implants superiorly.

The patient is maintained on antibiotics for 24 hours postoperatively. Massage is started at this time and is gradually increased. Vigorous exercises are avoided for the first few weeks. Postoperative massage allows the pocket to remain as large as possible. If a textured-surface implant has been used, less massage will be done.

Volume Adjustments

Volume adjustments are started as soon as the patient is pain-free, usually 2 to 3 days after surgery. A sterile technique is used, and a 23-gauge butterfly needle is inserted into the injection dome.

The reservoirs are usually removed anywhere between 2 and 6 months. One week prior to removal, approximately 20 to 50 cc saline will be removed. The reservoirs are removed under local anesthetic through the lateral third of the original incision.

Ptosis Correction with the Expander Implant

Mild to moderate degrees of ptosis can be improved by the following technique:

1. An inframammary incision is used
2. The implant is placed in a submuscular pocket.
3. The glandular tissue is then completely freed from the underlying muscle in order to facilitate redraping over the new breast mound.
4. The skin is taped postoperatively in an elevated position.

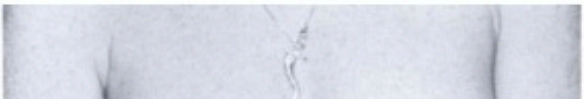

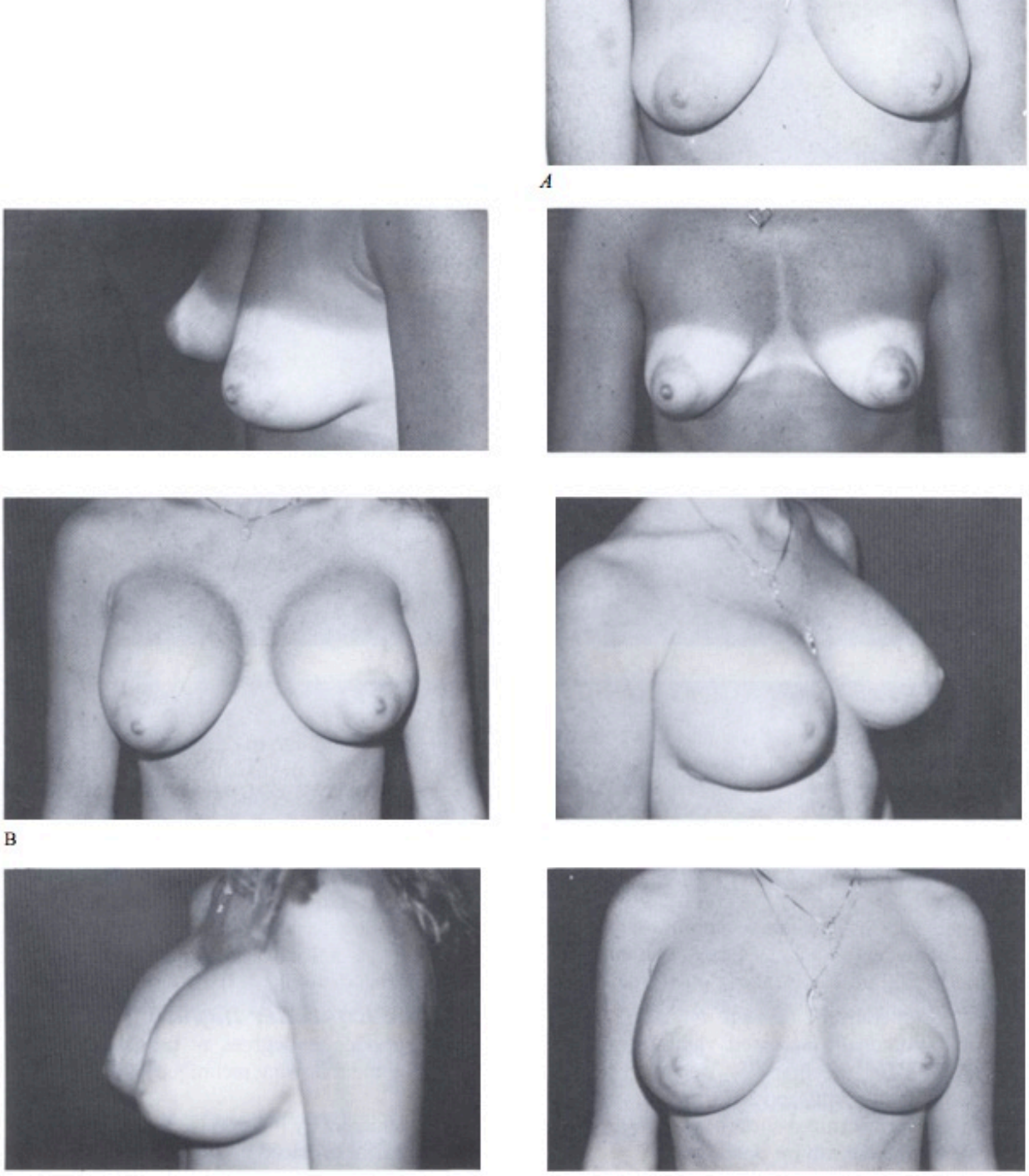

FIG. 11-27. A. Preoperative views showing ptosis, asymmetry, and narrow inframammary crease. B. Postoperative views showing overexpanded implants. C. Final result at 1 year following volume adjustment.

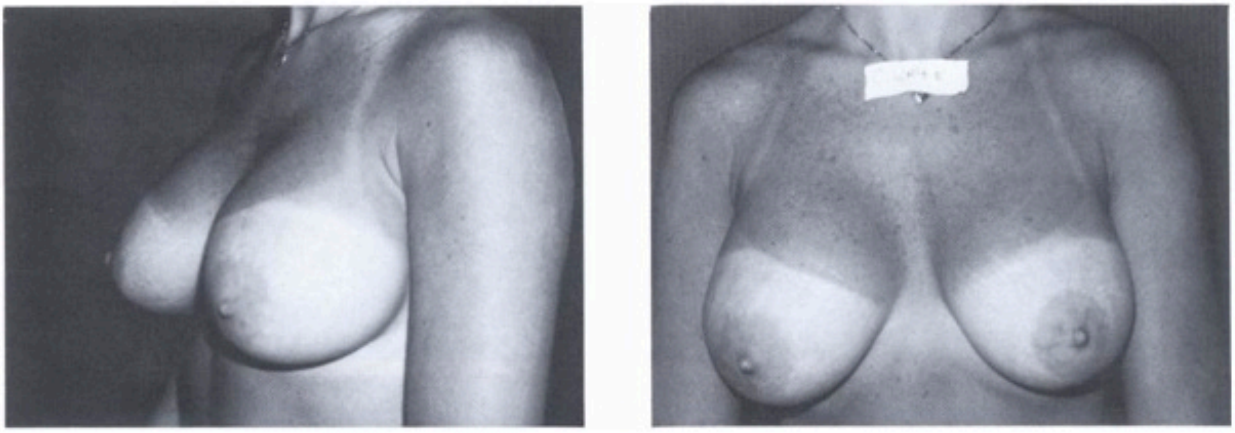

C

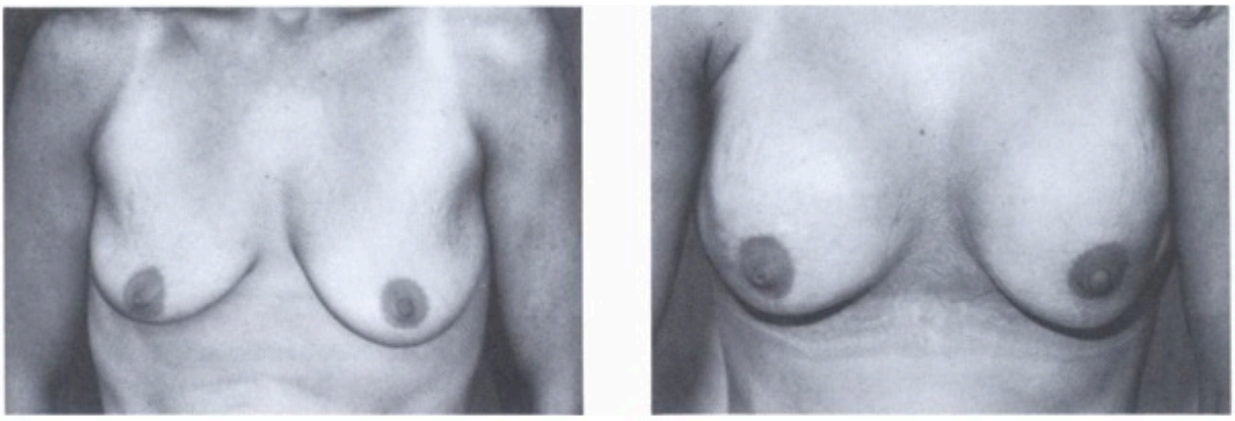

A

B

FIG. 11-28. *A. Preoperative view showing moderate ptosis. B. Postoperative result showing inadequate correction. C. Final result following further expansion.*

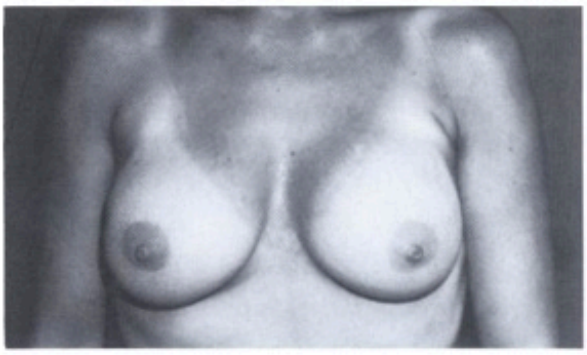

C

5. Postoperative overexpansion is carried out. This facilitates adhesion of the glandular tissue to the underlying muscle.

6. After several weeks, the volume can be reduced to the patient's satisfaction, allowing the patient to chose between size versus ptosis correction (Figs. 11 -27A,B, *C,* and 11 -28A,B, *C).*

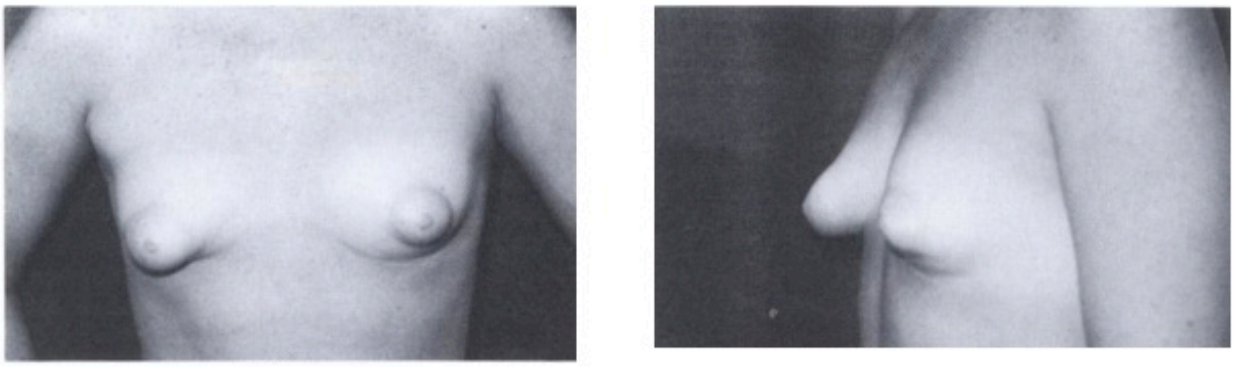

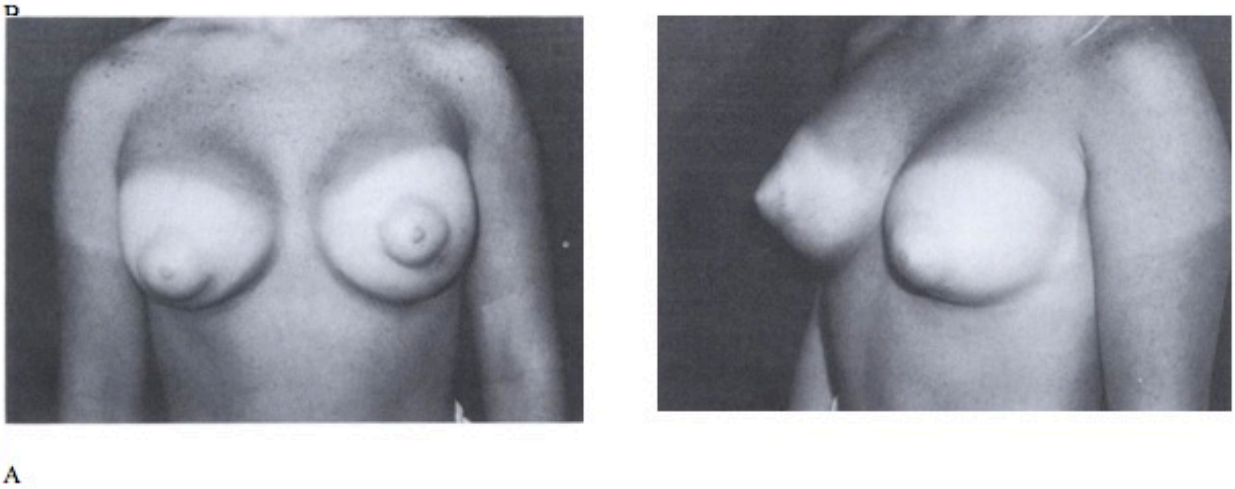

FIG. 11-29. *A. Preoperative views showing asymmetry and tubular deformity, PA and lateral views. B. Final result showing correction, PA and lateral views.*

Tubular Breast Deformity

A transareolar incision is usually used. Once again, the implant is placed in the submuscular plane. The granlular flap is then freed from the underlying muscle. The constriction ring around the areola can then be incised through the circumareolar incision. Postoperative overexpansion facilitates correction of the deformity (Fig. 11-29A,B).

Capsular Contracture

Recurrent capsular contracture is treated by open capsulotomy, placement of the expander implant, postoperative expansion, and maintenance of overexpansion for approximately 3 to 6 months. Once the capsule has matured, the volume is then reduced. It appears that splinting of the capsule postoperatively decreases the incidence of recurrent capsular contracture (Fig. 11-30A-E).

Suggested Readings

Becker, H. The permanent tissue expander. *Clin. Plast. Surg.* 14: 1987.

Becker, H. The expandable mammary implant: An update. *Perspect. Plast. Surg.* 3: 1989.

Becker, H. Breast augmentation using the expander mammary prosthesis. *Plast. Reconstr. Surg.* 79: 1987.

Cairns, T. S., and de Villiers, W. Capsular contracture after breast augmentation: A comparison between gel- and saline-filled protheses. *S. Afr. Med. J.* 57: 951, 1980.

Hetter, G. P. Satisfactions and dissatisfactions of patients with augmentation mammaplasty. *Plast. Reconstr. Surg.* 64: 151, 1979.

McGrath, M. H., and Burkhardt, B. R. The safety and efficacy of breast implants for augmentation mammaplasty. *Plast. Reconstr. Surg.* 74: 550, 1984.

Regnault, P., Baker, T. J., Gleason, M. C., et al. Clinical trial and evaluation of a proposed new inflatable mammary prothesis. *Plst. Reconstr. Surg.* 50: 220, 1972.

Tebbetts J. B. Transaxillary subpectoral augmentation mammaplasty: Long-term follow-up and refinements. *Plast. Reconstr. Surg.* 74: 636, 1984.

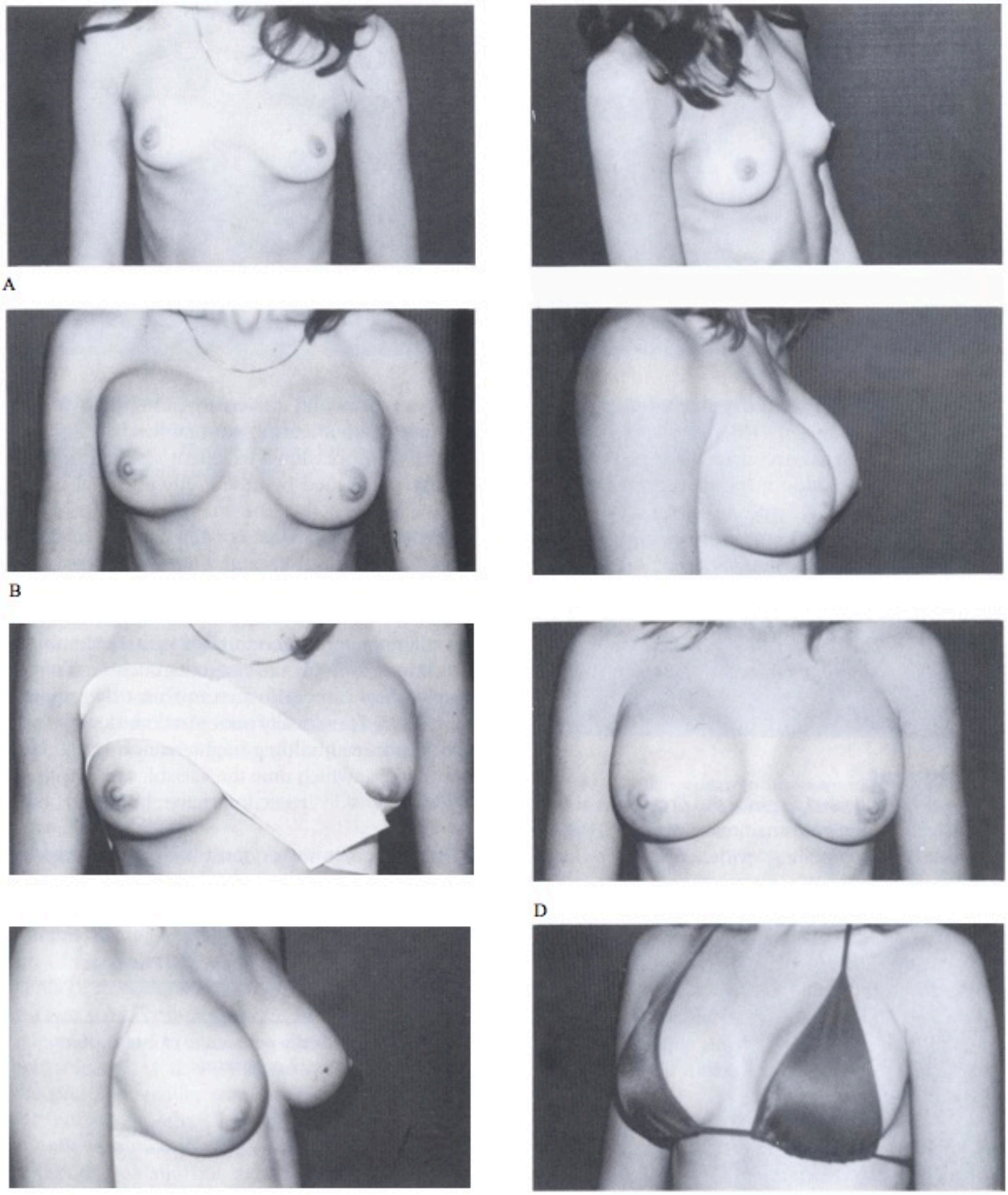

FIG. 11-30. A. PA and lateral views preoperatively. Note breast asymmetry. B. Right breast overexpanded postoperatively to correct asymmetry. C. Adjustment strap applied to further aid in lowering right breast. D. Final result, asymmetry corrected. E. Lateral view.