

# Subareolar Mastopexy: Update

Hilton Becker, MD  
Dr. Becker is in private practice in Boca Raton, FL.

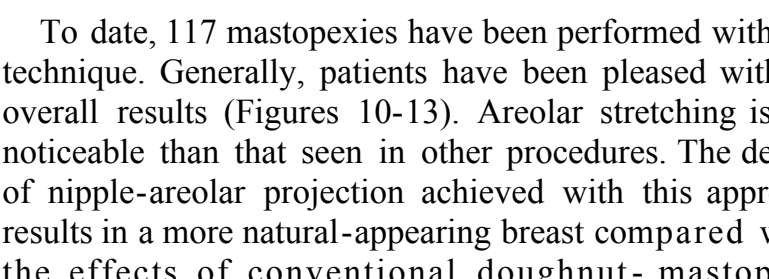
**Background:** A preliminary report on a new technique for dermal overlap subareolar mastopexy appeared in 2001. **Objective:** This paper reports on a series of 117 patients who underwent subareolar mastopexy and describes several modifications of the original technique. **Methods:** Preoperative markings defined the upper edge of the new areola position, the circumferential outline, and the outer edge of the areola. The skin was deepithelialized, and the areolar flap was elevated to the level of the nipple pedicle. Dissection was performed in the subdermal plane to the inframammary fold, the breast tissue was elevated, and the medial and lateral flaps were overlapped for mastopexy. Depending on the procedure, a wedge of tissue was removed for breast reduction or a submuscular pocket was created for placement of an implant. Closure of the areola incision was carried out with the use of 2 or 3 purse-string sutures. **Results:** Satisfactory results were achieved with few complications, including less areolar stretching and a higher degree of nipple-areolar projection compared with the results of conventional doughnut mastopexy. **Conclusions:** This technique provides excellent results for those patients who are willing to accept partial improvement of ptosis in order to minimize the scar. The degree of ptosis correction is not as marked as that achieved with the vertical or anchor mastopexy. (*Aesthetic Surg J* 2003;23:357-363)

The incisions used for the correction of breast ptosis have diminished in size from the standard anchor incision to the vertical mastopexy and to the circumareolar mastopexy.<sup>1-3</sup> The major problems seen with the circumareolar technique are widening and flattening of the areola, together with hypertrophic scarring. A new technique of dermal-overlap subareolar mastopexy was originally described in September 2001.<sup>4</sup> The technique involves advancing a dermal flap beneath the areola to reduce tension on the skin incision. Several nonabsorbable purse-string sutures are then placed on the advanced dermal flap to lend extra support to this area. The technique can be used for mild to moderate degrees of breast ptosis and mild degrees of mammomegaly. The technique has also been found to be beneficial in correcting tubular breast deformity. As experience has been gained, several modifications have been made. To date, 117 procedures have been performed, with a low rate of complications.

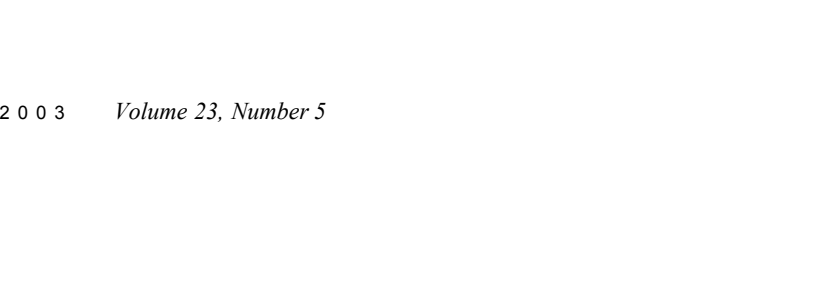
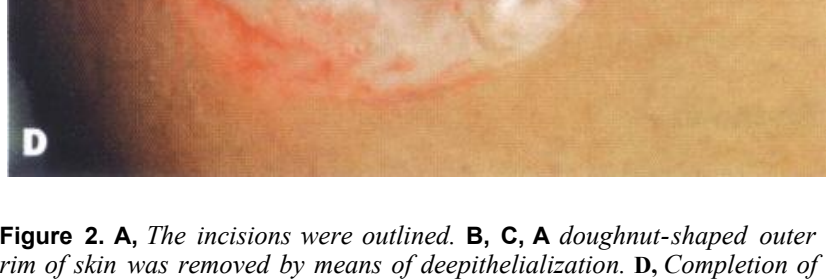
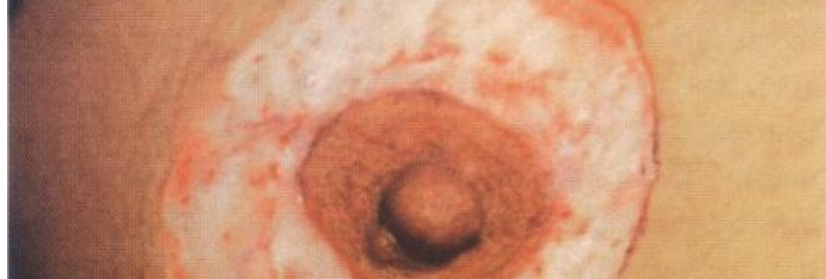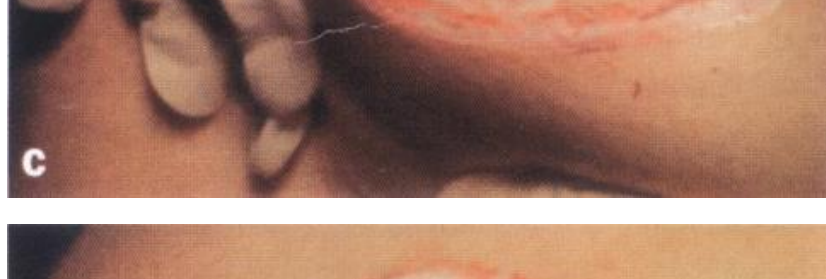**Methods**  
The degree of areola elevation was determined preoperatively by means of manual constriction of the skin. The upper edge of the new areola position was marked A (Figure 1). The circumferential outline was then marked around the areola, with marking A as the outer perimeter.

The outer edge of the areola was then outlined and marked B. Less areolar skin was to be resected than is removed in the standard circumareolar techniques. The skin between marking A and marking B was deepithelialized (Figure 2). The areolar flap was elevated as a myocutaneous flap up to the nipple pedicle (Figure 3). Dissection was in the relatively avascular intradermal plane, leaving dermis on the base as well as under the flap. If an internal mastopexy, reduction, or augmentation was performed, an incision was made through the dermis to the inframammary fold (Figure 4). The breast tissue was elevated off the muscle and a vertical incision made to the nipple pedicle. The medial and lateral flaps were overlapped for mastopexy (Figure 5). A wedge of breast tissue was removed for breast reduction, or a subglandular or submuscular pocket was created for placement of a breast implant. A suction drain was inserted when a subglandular or submuscular pocket was created. Closure of the areolar incision was carried out with 2 or 3 3-0 Tycron purse-string sutures (Figure 6).<sup>4</sup> In cases in which excess tension was present, a disc of Prolite Mesh (Atrium Medical Corp., Hudson, NH) was used successfully for added support (Figure 7).<sup>5,6</sup> The areolar flap was then returned to the plicated dermal base (Figure 8). Absorbable subdermal sutures may be used for closure because there is no tension on the areolar edge (Figure 9).

AESTHETIC SURGERY JOURNAL • SEPTEMBER/OCTOBER 2003 357



**Figure 1.** Preoperative skin markings. **A**, Outer incision; **B**, inner incision.



**Figure 2.** **A**, The incisions were outlined. **B**, **C**, A doughnut-shaped outer rim of skin was removed by means of deepithelialization. **D**, Completion of deepithelialization.

### Results

To date, 117 mastopexies have been performed with this technique. Generally, patients have been pleased with the overall results (Figures 10-13). Areolar stretching is less noticeable than that seen in other procedures. The degree of nipple-areolar projection achieved with this approach results in a more natural-appearing breast compared with the effects of conventional doughnut-mastopexy procedures. No loss of nipple sensation occurred in our series. Two patients required repeat surgery to correct insufficient nipple-areolar elevation.

The rate of complications was low. Two patients required scar revision caused by stretching of the areola. In 1 patient, a stitch abscess developed, requiring removal of the purse-string suture and later revision. In 2 cases, the areola had to be released because of hematoma. Partial loss of the areola, with resulting hypopigmentation, occurred in several cases. However, there was no total loss of an areola. Healing proceeded in all of the patients without major sequelae.

### Discussion

#### Many different techniques for circumareolar

mastopexy/reduction have been described.<sup>7,8</sup> These techniques rely on a nonabsorbable purse-string suture placed within the dermis of the outer incision. Although the areola can be effective, stretching and flattening of the areola often occurs because of failure of the purse-string suture. A means of enhancing the control of the purse-string technique was sought. The erector muscle layer within the areola receives its blood supply from the nipple. The areola, which is essentially a myocutaneous flap,

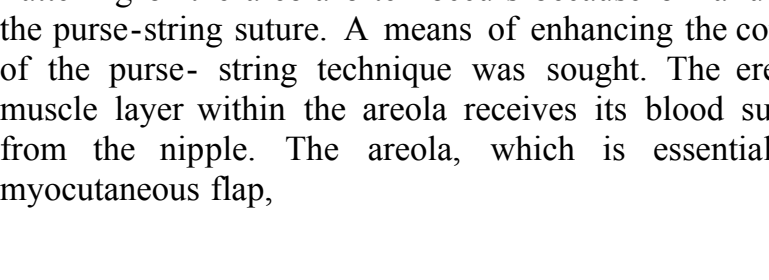
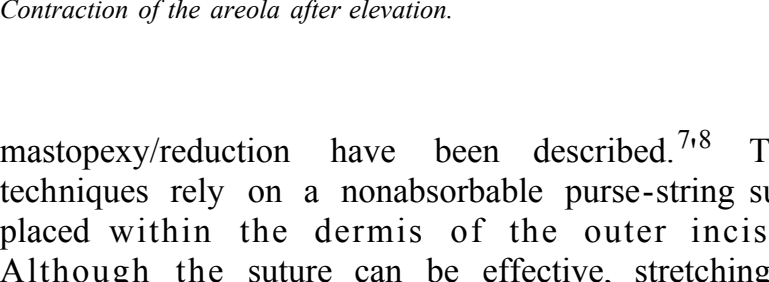
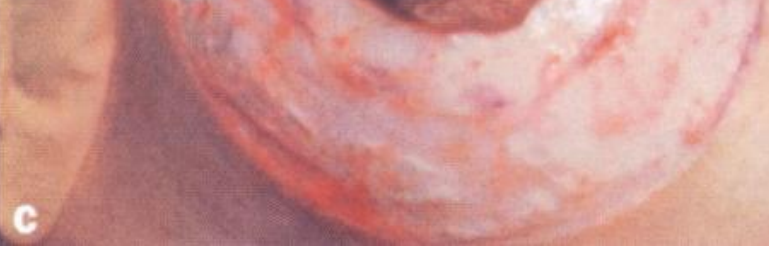can be elevated as described because of the blood supply it receives from the nipple pedicle. Teimourian described a technique of elevating the areola and existing tissue beneath it to correct tubular breast deformity.<sup>9,10</sup>

When the areola is elevated on a central pedicle, the underlying dermis is exposed. The dermal layer can be advanced beneath the areola with several purse-string sutures rather than just one. The areola is then secured on the advanced dermis, resulting in a dermal-to-dermal closure, which places tension on the dermal flap rather than on the skin edge. The areola is allowed to heal tension-free on the advanced dermal bed.

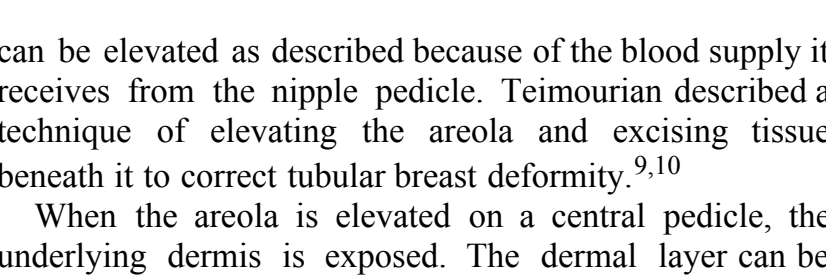
#### Conclusion

This procedure has been used successfully in the following situations: mastopexy, limited breast reduction, tubular breast deformity, augmentation mastopexy, breast asymmetry, and mastopexy after implant removal.

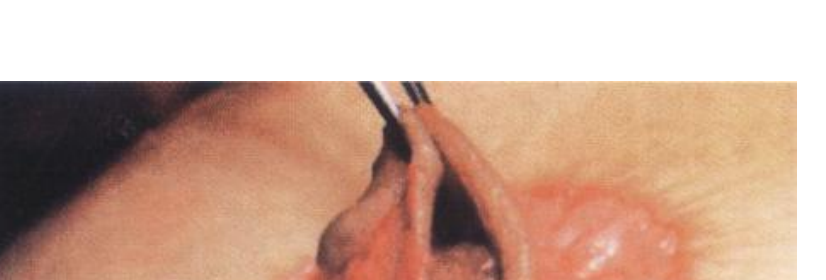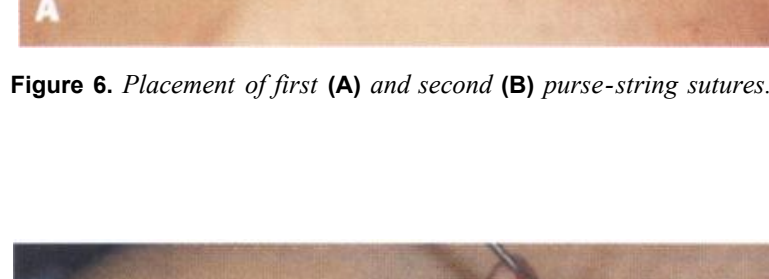
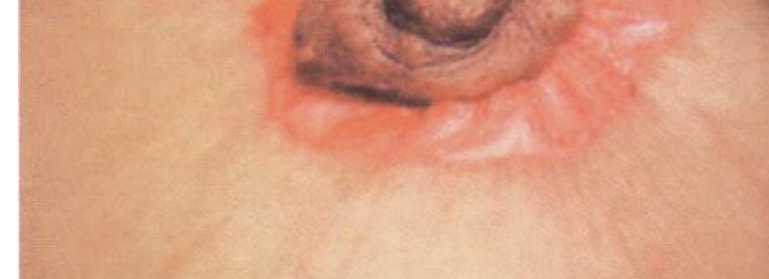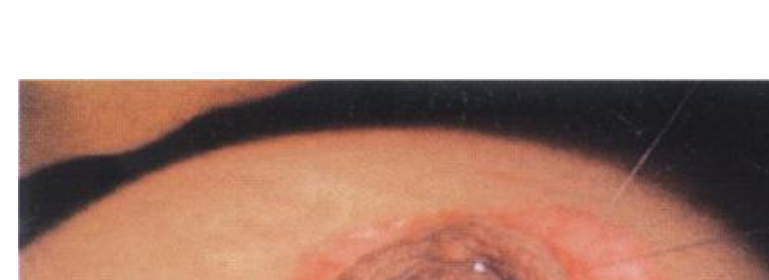Subareolar Mastopexy: Update AESTHETIC SURGERY JOURNAL • SEPTEMBER/OCTOBER 2003 359



**Figure 3.** **A**, **B**, The areolar flap was elevated on the nipple pedicle. **C**, Contraction of the areola after elevation.



**Figure 4.** An incision was made through the dermis to access the gland.



**Figure 5.** Incision of the glandular flap for internal mastopexy.

mastopexy/reduction have been described.<sup>7,8</sup> These techniques rely on a nonabsorbable purse-string suture placed within the dermis of the outer incision. Although the areola can be effective, stretching and flattening of the areola often occurs because of failure of the purse-string suture. A means of enhancing the control of the purse-string technique was sought. The erector muscle layer within the areola receives its blood supply from the nipple. The areola, which is essentially a myocutaneous flap,


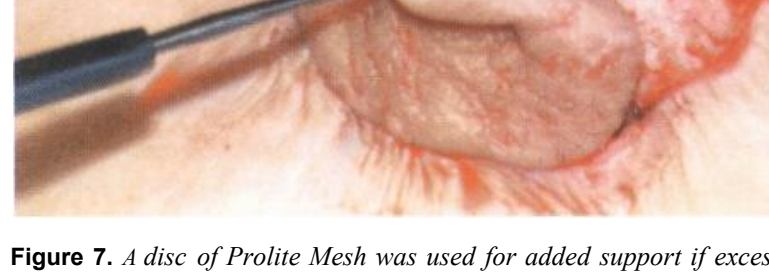
can be elevated as described because of the blood supply it receives from the nipple pedicle. Teimourian described a technique of elevating the areola and existing tissue beneath it to correct tubular breast deformity.<sup>9,10</sup>

When the areola is elevated on a central pedicle, the underlying dermis is exposed. The dermal layer can be advanced beneath the areola with several purse-string sutures rather than just one. The areola is then secured on the advanced dermis, resulting in a dermal-to-dermal closure, which places tension on the dermal flap rather than on the skin edge. The areola is allowed to heal tension-free on the advanced dermal bed.

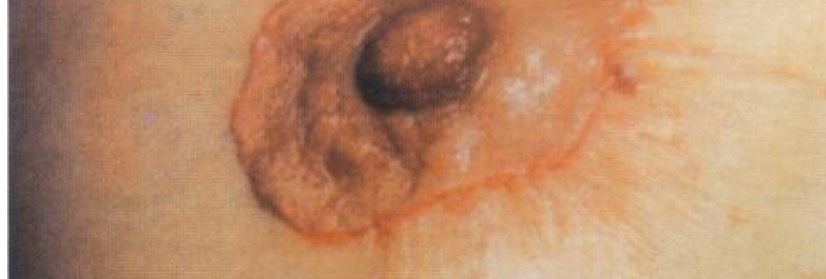
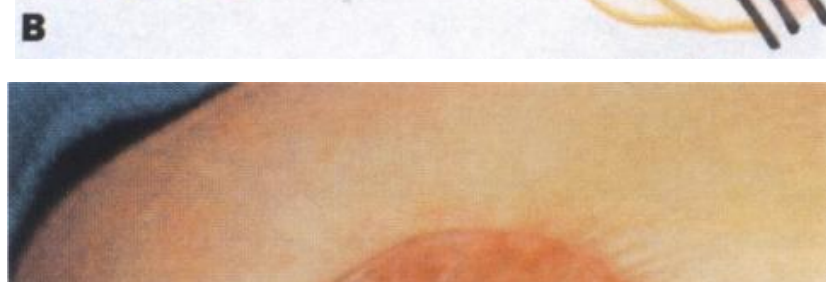#### Conclusion

This procedure has been used successfully in the following situations: mastopexy, limited breast reduction, tubular breast deformity, augmentation mastopexy, breast asymmetry, and mastopexy after implant removal.

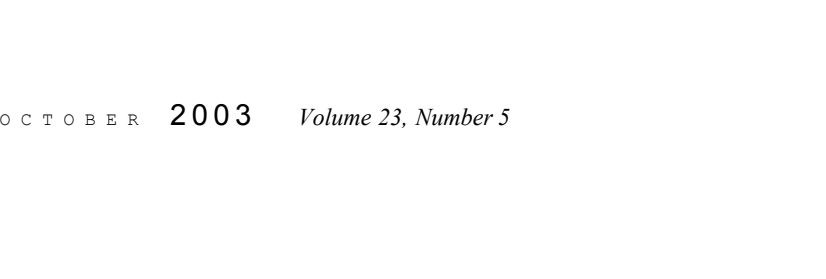
Subareolar Mastopexy: Update AESTHETIC SURGERY JOURNAL • SEPTEMBER/OCTOBER 2003 362



**Figure 6.** Placement of first (**A**) and second (**B**) purse-string sutures.

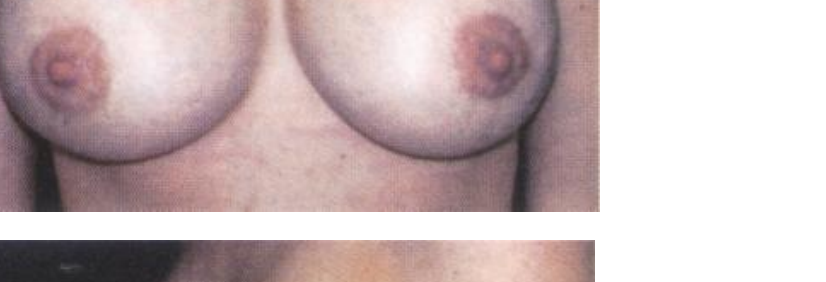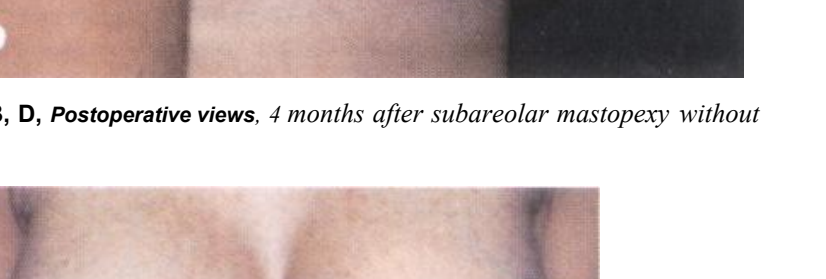
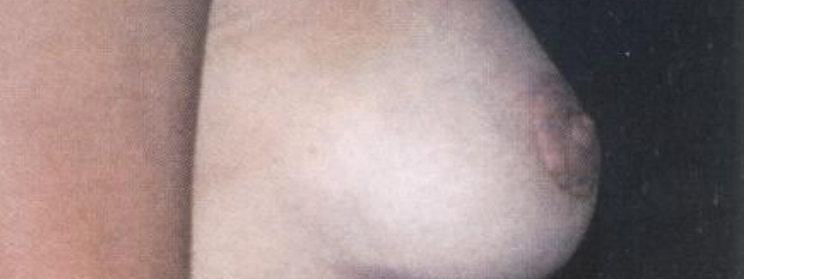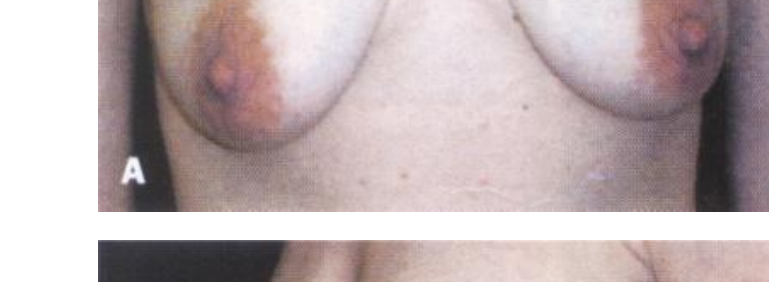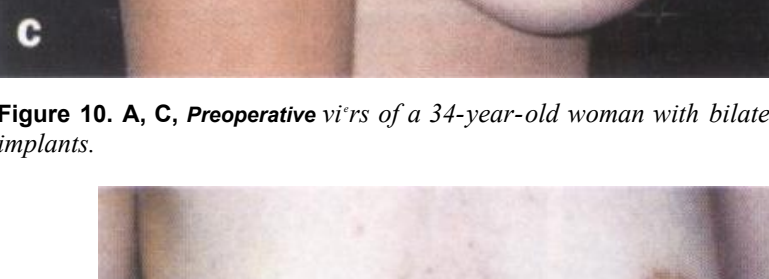


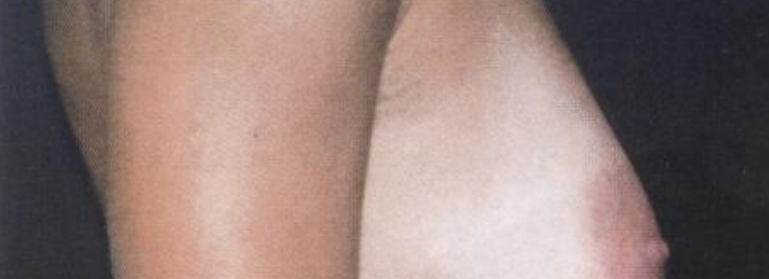**Figure 7.** A disc of Prolite Mesh was used for added support if excess tension was present.

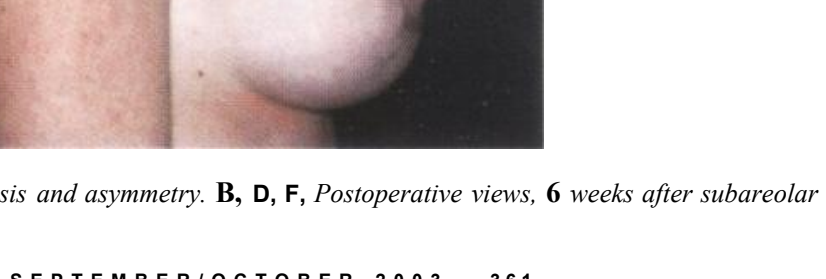
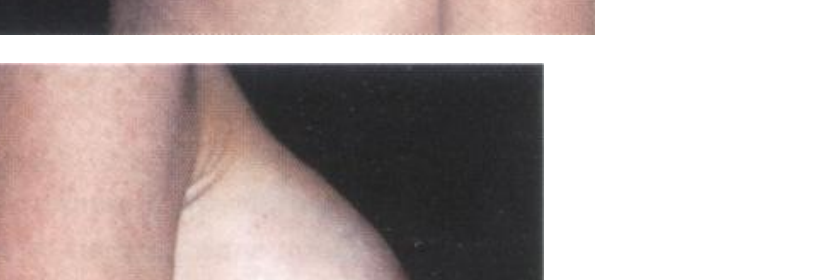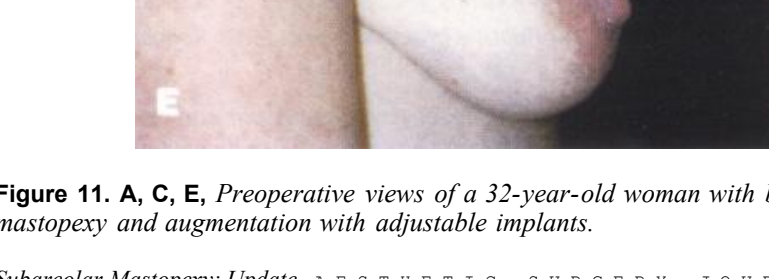

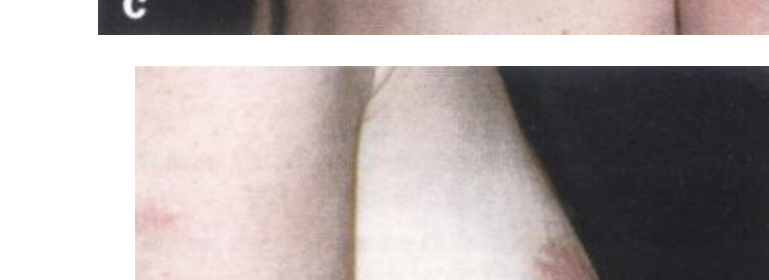
**Figure 8.** The dermis was plicated with 2 nonabsorbable purse-string sutures. **Figure 9.** **A**, **C**, Tension-free closure.

Subareolar Mastopexy: Update AESTHETIC SURGERY JOURNAL • SEPTEMBER/OCTOBER 2003 362

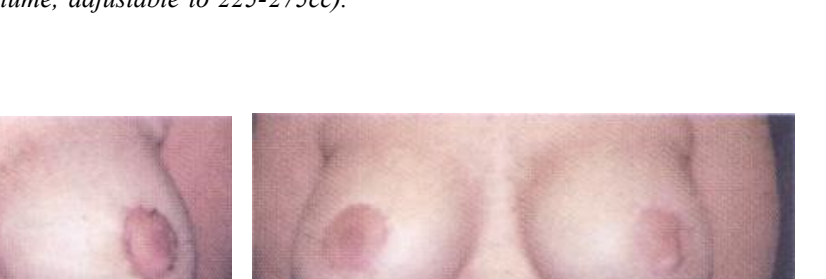
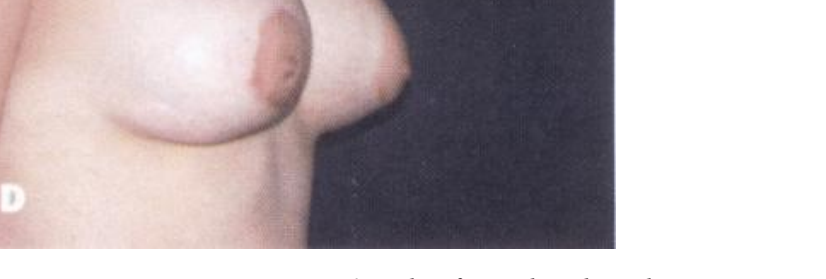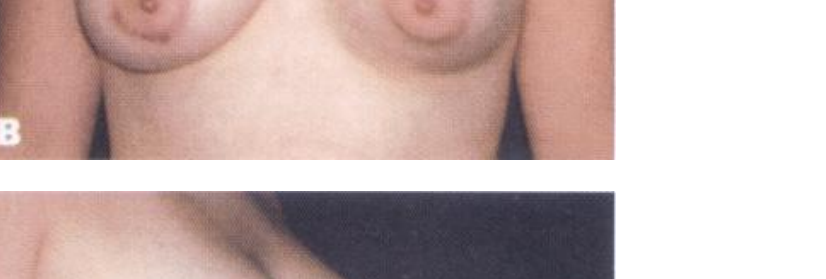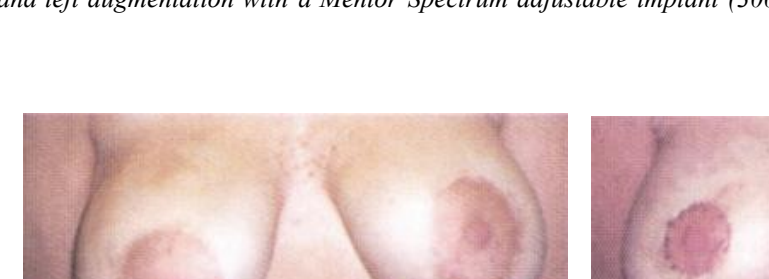


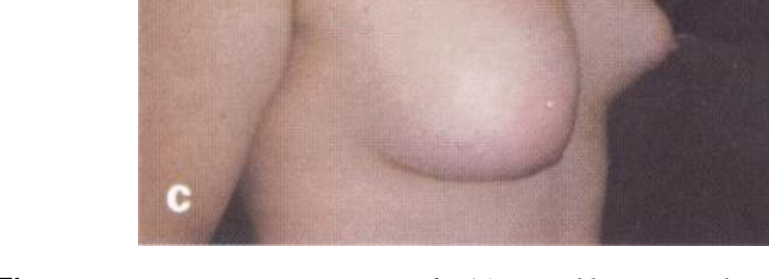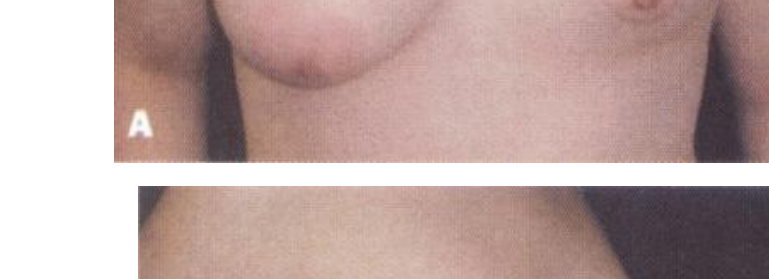**Figure 10.** **A**, **C**, Preoperative views of a 34-year-old woman with bilateral ptosis. **B**, **D**, Postoperative views, 4 months after subareolar mastopexy without implants.

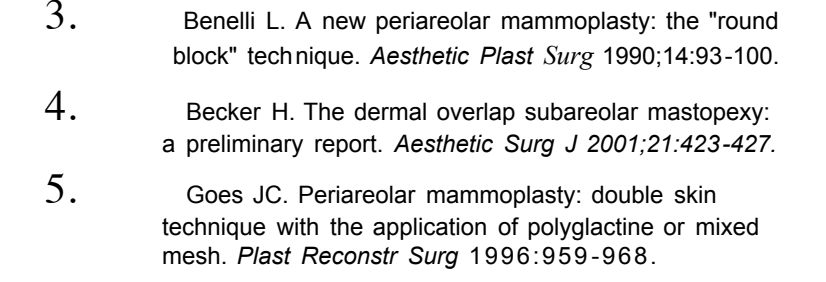
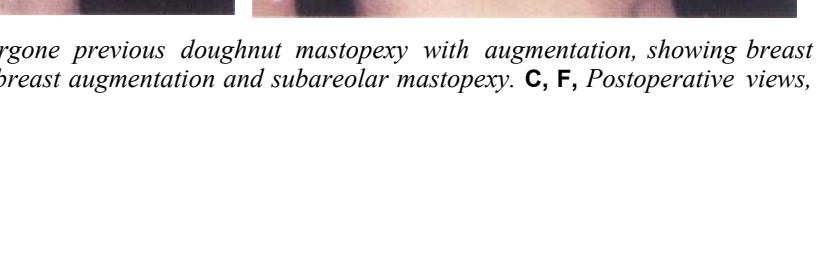
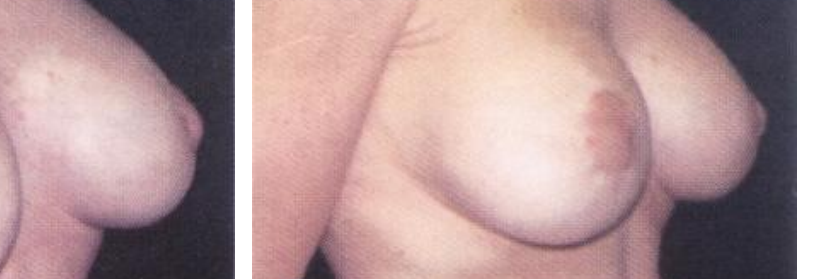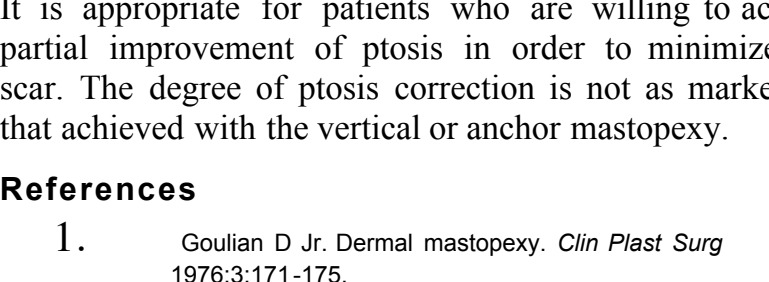
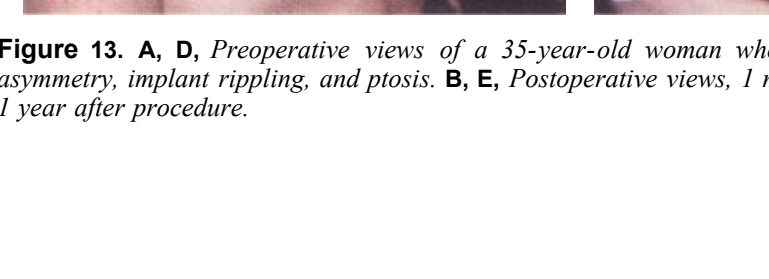

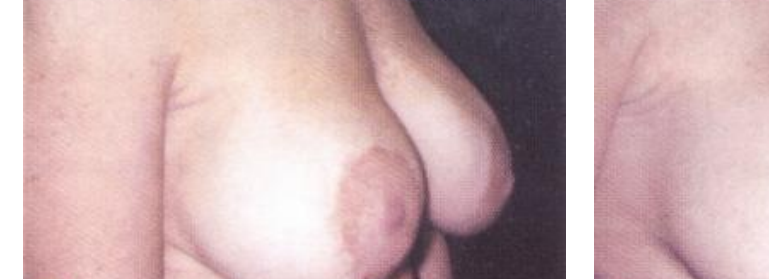
**Figure 11.** **A**, **C**, Preoperative views of a 32-year-old woman with bilateral ptosis and asymmetry. **B**, **D**, **F**, Postoperative views, 6 weeks after subareolar mastopexy and augmentation with adjustable implants.

Subareolar Mastopexy: Update AESTHETIC SURGERY JOURNAL • SEPTEMBER/OCTOBER 2003 361



**Figure 12.** **A**, **D**, Preoperative views of a 16-year-old woman with Poland syndrome. **B**, **D**, Postoperative views, 6 weeks after right subareolar mastopexy and left augmentation with a Mentor Spectrum adjustable implant (300 cc total volume, adjustable to 225-275cc).



**Figure 13.** **A**, **D**, Preoperative views of a 35-year-old woman who had undergone previous doughnut mastopexy with augmentation, showing breast asymmetry, implant rippling, and ptosis. **B**, **E**, Postoperative views, 1 month after breast augmentation and subareolar mastopexy. **C**, **F**, Postoperative views, 1 year after procedure.

It is appropriate for patients who are willing to accept partial improvement of ptosis in order to minimize the scar. The degree of ptosis correction is not as marked as that achieved with the vertical or anchor mastopexy.

### References

- Goulian D Jr. Dermal mastopexy. *Clin Plast Surg* 1976;3:171-175.
- Becker H, Storm van Leeuwen JB. The correction of breast ptosis with the expander mammary prosthesis. *Ann Plast Surg* 1990;24:489-497.
- Benelli L. A new periareolar mammoplasty: the "round block" technique. *Aesthetic Plast Surg* 1990;14:93-100.
- Becker H. The dermal overlap subareolar mastopexy: a preliminary report. *Aesthetic Surg J* 2001;21:423-427.
- Goes JC. Periareolar mammoplasty: double skin technique with the application of polyglactine or mixed mesh. *Plast Reconstr Surg* 1990;85:93-98.
- Goes JCS. Periareolar mastopexy and reduction with mesh support. In: *Breast Surgery*. Philadelphia, PA: Raven-Lippincott; 1998:697-708.
- Felicia Y. Periareolar reduction mammoplasty. *Plast Reconstr Surg* 1991;88:789-798.
- Guber RP, Jones HW Jr. The "donut" mastopexy: indications and complications. *Plast Reconstr Surg* 1980;65:34-38.
- Teimourian B, Adham MN. Surgical correction of the tubular breast. *Ann Plast Surg* 1983;10:190-193.
- Teimourian B. Congenital anomalies of nipple and areola. In: *Georgiade NG, ed. Aesthetic Breast Surgery*. New York, NY: Lippincott; 1983:347-360.

Accepted for publication April 28, 2003.  
Reprint requests: Hilton Becker, MD, 5458 Town Center Road, Suite 101, Boca Raton, FL 33486; e-mail: hbecker@bma.com.

Copyright © 2003 by The American Society for Aesthetic Plastic Surgery, Inc. 1090-820X/2003/\$30.00 + 0  
doi:10.1067/maj.2003.71